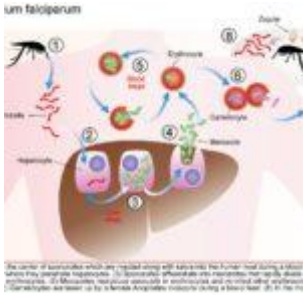


Two year old with spiking fevers and depressed level of consciousness



- [Patient Presentation](#)
- [History](#)
- [Differential diagnosis](#)
- [Examination](#)
- [Investigations](#)
- [Discussion](#)
- [Treatment](#)
- [Final outcome](#)
- [References](#)
- [Evaluation - Questions & answers](#)

Patient Presentation

A 2 year old boy presented to a district hospital with decreased oral intake, listlessness and fever. On arrival he was adequately resuscitated but continued to have spiking fevers and a depressed level of consciousness.

Acknowledgement

This case study was kindly provided by Barclay Stewart, Medical University of South Carolina, Fogarty International Clinical Research Scholar, Nairobi, Kenya

History

Six months ago the patient presented to the hospital with a two day history of irritability, decreased appetite, discomfort on lying down, recurrent fever, profuse sweating and diarrhea, no vomiting. On admission he was lethargic and dehydrated which worsened over a few hours and culminated in a seizure. He had no prior history of seizures. He was then diagnosed with severe malaria. He was treated appropriately and discharged 2 weeks later with no residual effects.

Past medical and surgical history

- There is no additional significant medical or surgical history.
- Road to health card shows all growth parameters to be within normal limits, with all vaccinations up to date.

Family and social history

- He lives with his mother, father, and two older siblings who are all healthy.
- His mother was recently tested and is HIV negative; his father has not been tested.
- Their home, which has electricity and water, is located in a low-lying area near Musina, a town in South Africa's Limpopo province. This is the country's most northerly located town, with a seasonal high rate of malaria transmission from October through May.

Travel History

No travel outside of Musina since birth.

Differential diagnosis

- Encephalitis
- Meningitis
- Gastroenteritis with severe dehydration

- Pneumonia
- Toxic Shock Syndrome
- Typhoid Fever
- Brucellosis
- Relapsing Fever
- Katayama Fever
- Urinary tract infection
- Bacteraemia

Examination

On appearance the child is miserable and toxic looking.

Vitals

- Pulse – 166
- Respiratory Rate – 34
- Temperature – 39.8
- Pulse-Oxygen – 95%

Height and weight were in the 65 percentile

General

- Eyes were sunken and jaundiced.
- No lymphadenopathy

ENT

- Erythematous, non bulging tympanic membranes.
- Non-inflamed nasal passage, no discharge.
- Pale oral mucosa

Eyes

- No papilloedema
- No retinal haemorrhages

Chest

- Midline trachea

- Chest shape normal in appearance, tachypnoea present
- Mild subcostal retractions.
- Clear on auscultation bilaterally.

Cardiovascular

- Tachycardia with a regular rhythm.
- Normal S1 and S2 with a 2/6 mid systolic murmur best auscultated over the upper left sternal border with minimal radiation.
- Bounding pulses felt radially, femorally and dorsalis pedis
- Capillary refill within 2 seconds.

Abdomen

- Normal on inspection.
- Bowel sounds diminished but present.
- No hepatomegaly.
- 4cm splenomegaly.

Neurological

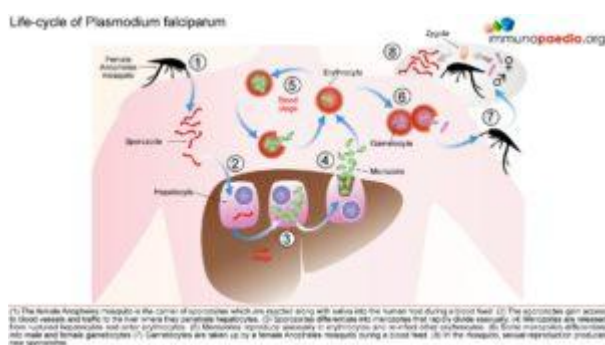
- Child listless though attempts to follow commands.
- Not resisting or crying in response to aggravating stimuli.

Investigations

Examination	Value	Normal Limits
WBC	12	(4 – 12 x 10 ⁹ /l)
HB	7.2	(12.1 – 15.2 g/l)
HCT	0.22	(.31 - .42 g/l)
Platelets	222	(140 – 450 x 10 ⁹ /l)
LDH	294	(70 – 250 U/l)

Examination	Value	Normal Limits
Haptoglobin (free serum)	23	(27-139 mg/dl)
Reticulocyte Count	6	(0.8 – 4% RBC)
Metabolic Panel		
AST	52	(5 – 35 U/l)
ALT	101	(25 – 120 U/l)
Total Bilirubin	2.1	(0.1 – 1.3 mg/dl)
Direct Bilirubin	0.1	(0.0 – 0.3 mg/dl)
Sodium	143	(135 – 147 mmol/l)
Potassium	4.0999999999999996	(3.5 – 5.1 mmol/l)
Bicarbonate	25	(22 – 33 mmol/l)
Chloride	93	(95 – 107 mmol/l)
Anion Gap	25	(8 – 16 meg/l)
Creatinine (serum)	1.8	(0.7 – 1.3 mg/l)
BUN (serum)	21	(7 – 20 mg/dl)
Glucose (serum)	50	(65 -110 mg/dl)
Urine Analysis		
Spec. Gravity	1.0289999999999999	(1.010 – 1.030)
pH	6.3	(4.8 – 7.5)
Ketones	Trace	Absent
Protein	Trace	Absent
Bilirubin	Trace	Absent
Glucose	Absent	Absent
RBC	Trace	Absent

include holoendemic where the rate is >75% (transmission of infection is year round and the bulk of mortality is seen in infants), hyperendemic where the rate is 51-75% (mortality is also mostly seen in infants), mesoendemic where the rate is 11-50% (regular seasonal transmission affecting infants, toddlers and adults who develop chronic ill health) and hypoendemic which is <10% (occasional epidemics, whole population is susceptible to severe and fatal disease). Clinical immunity also fails if a person moves away from an endemic area and during pregnancy.



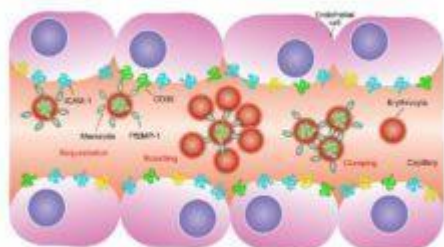
Parasitology – Malaria Life-Cycle

The female Anopheles mosquito inoculates the host with 10 to 100 malaria sporozoites from her salivary glands during a blood meal. These microscopic motile forms of the malaria parasite are carried via the bloodstream to the liver. Within 30 minutes, those sporozoites not bound by previously formed antibodies, invade and begin replicating in hepatocytes. Parasites not destroyed by cytotoxic T lymphocytes in the liver replicate for 2-10 days creating merozoites. Tens of thousands of merozoites are released into the bloodstream as the hepatocyte bursts. Each merozoite is then able to bind, invade, and infect erythrocytes. After red blood cell (RBC) infection, each merozoite matures to form a highly metabolically active trophozoite, which replicates asexually to become multinucleate schizonts. As the schizonts enlarge they rupture erythrocytes 48 hours after their formation which results in 20-30 new merozoites which continue the cycle. Some sexual forms of the parasite develop during this erythrocytic stage; these gametocytes are responsible for infecting the

salivary glands of female *Anopheles* mosquitoes. The gametes mature into ookinetes then into an oocyst. The oocyst ruptures and releases sporozoites which can then infect another host during a blood meal.

Adhesion of infected erythrocytes to vascular endothelial cells

immunopaedia.org

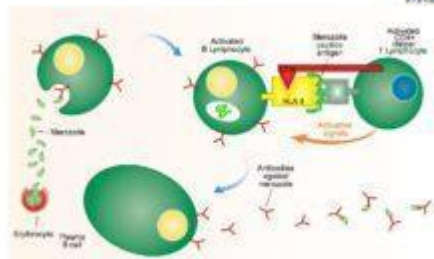


Infected erythrocytes express parasite derived PIRP-1 proteins on the cell surface. These proteins have high affinity for endothelial receptors such as CD36 and ICAM-1 expressed on vascular endothelial cells. Binding of infected erythrocytes to these receptors is sequestration allows escape from circulation. In the spleen where infected cells are selected and destroyed. In addition, infected erythrocytes can also adhere to uninfected erythrocytes. Clumping of infected erythrocytes can also occur. Clumping together these cause blockages in blood capillaries that can lead to cerebral malaria, kidney complications, diarrhoeal illness or respiratory distress.

Pathogenesis and Clinical Features

A person's first infection usually creates no symptoms for 7-10 days, which is followed first by nonspecific symptoms such as headache, fatigue, abdominal discomfort and muscle aches. This is then followed by fever. During this latent period, parasite maturation occurs in the liver and parasites undergo a cycle of blood stage replication. Symptoms begin when the parasites undergoing an asexual blood cycle, reach threshold density sufficient to initiate the host's pathogenic immune response process. Fever, malaria's hallmark, is due to parasite-derived molecules released from ruptured host cells. These molecules activate host inflammatory cells, such as macrophages, which secrete pro-inflammatory pyrogenic cytokines such as interleukin (IL)-1 and tumor necrosis factor (TNF)- α . As parasites synchronise their replication cycles the fever becomes periodic. Although childhood febrile convulsions can occur, generalised seizures are typically associated with *P. falciparum* infections and may herald cerebral malaria. Splenomegaly results from massive reticuloendothelial system activation to clear parasitised erythrocytes. Mild hepatomegaly is common in young children, while mild jaundice is more common in adults. Anaemia is also common and is partly due to the phasic rupture of RBCs by mature schizonts, splenic sequestration of red blood cells and ineffective erythropoiesis.

Antigenic variation of merozoite surface proteins

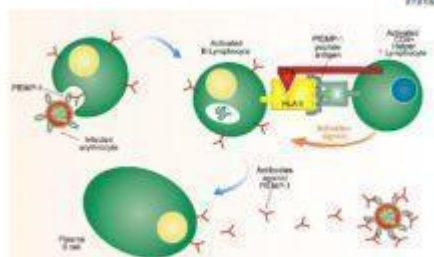


Antibody responses to cell surface proteins on merozoites are hampered by the antigenic variation of these proteins such as merozoite surface protein 1 (MSP-1). Merozoites alter forms of MSP-1 and express them on the surface of the parasite and expression of these proteins varies after each generation. New antibody responses are therefore needed when a different MSP-1 protein is expressed. In addition, CD44 receptor T lymphocyte responses which give activation signals to B lymphocytes are hampered as RLA class II antigen presentation. Variation of the RLA class II epitope when a different protein is expressed also affects the CD44 receptor T lymphocyte response.

Parasitised erythrocytes circulate to the microvasculature where they bind to the scavenger receptor CD36 or the intercellular adhesion 1 (ICAM-1) and occlude microvessels. Binding of

infected erythrocytes to these receptors (sequestration) allows the cells to escape from circulation to the spleen where infected cells are detected and destroyed. In addition, infected erythrocytes can also stick to uninfected erythrocytes (rosetting) or infected erythrocytes can stick together (clumping). In particular, parasitized RBCs adhere to the endothelial lining of capillaries in the brain, kidneys, gut and liver. Inflammation caused by these parasite-receptor interactions and release of immune stimulatory molecules from infected RBCs upon rupture are thought to be responsible for organ specific pathology such as cerebral malaria, renal disease, Blackwater Fever (due to widespread intravascular haemolysis giving rise to dark urine) and respiratory distress

Antigenic variation of erythrocyte surface proteins



Infected erythrocytes express parasite derived cell surface proteins such as PEMP-1. Antibody responses to the protein occurs and allows infected erythrocytes to be sequestered and destroyed. However, the genome of the parasite encodes multiple variants of the PEMP-1 protein and expresses a different protein after each generation thus evading previous antibody responses to the PEMP-1 protein. In addition, CD44 receptor T lymphocyte responses which give activation signals to B lymphocytes are hampered as RLA class II antigen presentation. Variation of the RLA class II epitope when a different protein is expressed also affects the CD44 receptor T lymphocyte response.

Clinical Features of Severe Falciparum Malaria

Correctly treated uncomplicated *P. falciparum* carries a mortality rate of 0.1%. When organ dysfunction or parasitaemia of >3% occurs mortality also

increases dramatically. These manifestations, which were also seen in this clinical case, include:

Cerebral Malaria

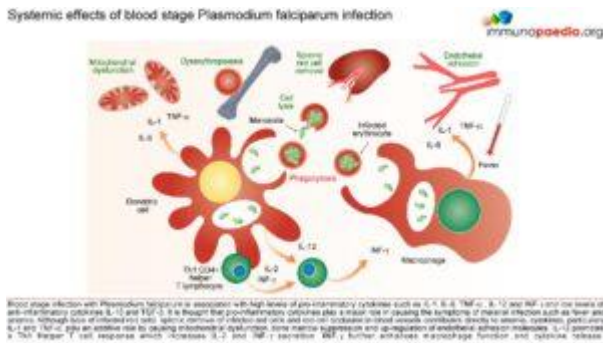
Onset may be gradual or sudden following a convulsion. Features include obtundation, delirium, abnormal behaviour and coma. Focal neurologic signs and meningism do not typically occur. Fifteen percent of children who survive cerebral malaria, especially when associated with hypoglycaemia, coma

and anaemia will have some residual neurologic deficit.

Hypoglycaemia

Common complication that is associated with a poor prognosis, particularly in children and pregnant women. Hypoglycaemia is due to a failure of hepatic gluconeogenesis and an increase in glucose consumption by host and parasite. This may manifest as an added complication during treatment as Quinine is also a potent stimulator of insulin secretion.

Systemic effects of blood stage *Plasmodium falciparum* infection



Lactic Acidosis

Coexists with hypoglycaemia and contributes to death. Caused by anaerobic glycolysis in tissues where parasites interfere with microcirculation, cytokine induced mitochondrial

dysfunction, hypovolaemia, lactate production by parasites and poor hepatic and renal clearance.

Haematologic Pathology

Anaemia due to increased destruction and removal of red blood cells and dyserythropoiesis.

Mild thrombocytopenia

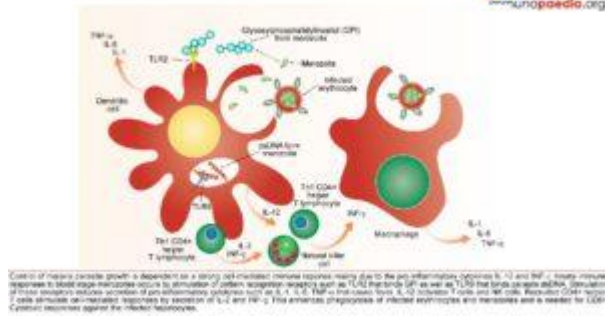
Mild coagulation abnormalities

Bleeding and DIC in more severe cases

Renal pathology

Interference in microcirculation resulting in tubular necrosis and acute renal failure, more common in adults.

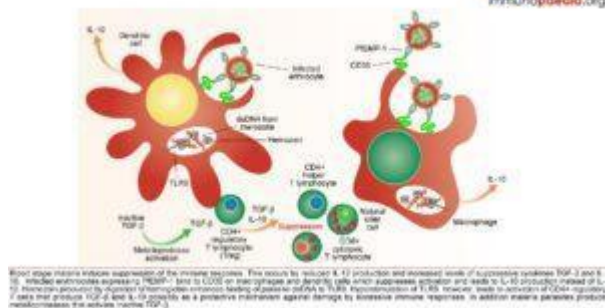
Host Response-Immunology



The innate immune responses have already been discussed above. Regarding acquired immune responses many studies show that antibodies and T cells are vital to the development of a protective immune

response against malaria infection. Specific immune responses are required to defuse the infection at multiple points in the parasite life cycle.

- Antibody responses are induced during the sporozoite stage. Antibody bound sporozoites are prevented from invading hepatocytes.
- CD8+ T cells have been shown to be cytotoxic against maturing sporozoite infected liver cells.
- Both of these responses are potentially able to terminate the infection before the onset of clinical disease caused by the release of merozoites from hepatocytes and subsequent RBC invasion and rupture.
- CD4+ T cells are a requisite for the production of merozoite neutralising antibodies by B cells and the activation of macrophages which secrete interferon (INF) γ to enhance parasitized RBC.
- The host is also able to develop transmission-blocking antibodies directed to gametocyte specific antigens. These antibodies hinder the development of the parasite within the mosquito vector, thereby preventing further infections. Though this immune response is not particularly valuable to the infected host, it does assist in reducing population level transmission.



Malaria has evolved unique strategies to evade the host immune system and is therefore able to cause repeated and serious infections. To overcome and control this disease one important aspe

ct is to develop an efficacious and safe vaccine. In order to do this it is necessary to understand the host immune responses and the immune evasion techniques that malaria employs.

Download images for this case



[Plasmodium Falciparum Malaria](#)

1 file(s) 828.07 KB

[Download](#)

Treatment

It is recommended that patients receive prompt and effective treatment. Ideally, treatment should be initiated in a hospital setting. The choice of chemotherapy for malaria is dependent on the severity of disease, the known or suspected resistance pattern of the parasite in the area where the malaria infection was acquired, the species of parasite, patient characteristics (age, pregnancy, co-morbidity, allergies, other medications) and the presence or absence of vomiting. In South Africa, malaria treatment varies in the different provinces due to differences in the resistance patterns. These treatment guidelines may not be appropriate for infections contracted in other countries with high levels of multi-drug resistance.

Download images for this case



[Plasmodium Falciparum Malaria](#)

1 file(s) 828.07 KB

[Download](#)

Final outcome

The patient was treated with IV artesunate and anti-pyretics for 3 days. IV antibiotics were started on admission as there was no confirmatory diagnosis at the time and culture results were not yet available. On the third day the child was markedly improved. He was started on a full course of mefloquine on receiving laboratory results which confirmed infection with *P.falciparum*. Upon discharge there were no neurologic sequelae. He and his family were counseled on the use of insecticide-treated bed nets and indoor residual spraying.

Download images for this case



[Plasmodium Falciparum Malaria](#)

1 file(s) 828.07 KB

[Download](#)

References

Guerin, P.J., et al. (2002). Malaria: current status of control, diagnosis, treatment, and a proposed agenda for research and development. *Lancet Infect Dis.* 2(9): p. 564-73.

[Link to Abstract](#)

Ferreira, M.U et al. (2004). Antigenic diversity and immune evasion by malaria parasites. Clin Diagn Lab Immunol. 11(6): p. 987-95.

[Link to Abstract](#)

May, J. et al. (1999). High rate of mixed and subpatent malarial infections in southwest Nigeria. Am J Trop Med Hyg. 61(2): p. 339-43.

[Link to Abstract](#)

Rosenberg, R. et al. (1990). An estimation of the number of malaria sporozoites ejected by a feeding mosquito. Trans R Soc Trop Med Hyg. 84(2): p. 209-12.

[Link to Abstract](#)

Ponnudurai, T. et al. (1982). Mosquito transmission of cultured Plasmodium falciparum. Trans R Soc Trop Med Hyg. 76(2): p. 278-9.

[Link to Abstract](#)

Ferreira, M.U et al. (1998). The IgG-subclass distribution of naturally acquired antibodies to Plasmodium falciparum, in relation to malaria exposure and severity. Ann Trop Med Parasitol. 92(3): p. 245-56.

[Link to Abstract](#)

Nardin, E.H et al. (1993). T cell responses to pre-erythrocytic stages of malaria: role in protection and vaccine development against pre-erythrocytic stages. Annu Rev Immunol. 11: p. 687-727.

[Link to Abstract](#)

Nardin, E.H. et al. (1982). Circumsporozoite proteins of human malaria parasites Plasmodium falciparum and Plasmodium vivax. J Exp Med. 156(1): p. 20-30.

[Link to Abstract](#)

Inselburg, J. (1983). Gametocyte formation by the progeny of

single *Plasmodium falciparum* schizonts. J Parasitol. 69(3): p. 584-91.

[Link to Abstract](#)

Aitman, T.J. et al. (2000). Malaria susceptibility and CD36 mutation. Nature. 405(6790): p. 1015-6.

[Link to Abstract](#)

Jenkins, N. et al. (2007). *Plasmodium falciparum* intercellular adhesion molecule-1-based cytoadherence-related signaling in human endothelial cells. J Infect Dis. 196(2): p. 321-7.

[Link to Abstract](#)

McCormick, C.J. et al. (1997). Intercellular adhesion molecule-1 and CD36 synergize to mediate adherence of *Plasmodium falciparum*-infected erythrocytes to cultured human microvascular endothelial cells. J Clin Invest. 100(10): p. 2521-9.

[Link to Abstract](#)

Miller, L.H. et al. (2002). The pathogenic basis of malaria. Nature. 415(6872): p. 673-9.

[Link to Abstract](#)

Abdel-Latif, M.S. et al. (2003). Antibodies to *Plasmodium falciparum* rifin proteins are associated with rapid parasite clearance and asymptomatic infections. Infect Immun. 71(11): p. 6229-33.

[Link to Abstract](#)

Good, M.F. et al. (1998). Pathways and strategies for developing a malaria blood-stage vaccine. Annu Rev Immunol. 16: p. 57-87.

[Link to Abstract](#)

Hoffman, S.L. et al. (1998). Sporozoite vaccine induces

genetically restricted T cell elimination of malaria from hepatocytes. Science. 244(4908): p. 1078-81.

[Link to Abstract](#)

Snewin, V.A et al. (1995). Transmission blocking immunity in Plasmodium vivax malaria: antibodies raised against a peptide block parasite development in the mosquito vector. J Exp Med. 181(1): p. 357-62.

[Link to Abstract](#)

Hisaeda, H. et al. (2005). Malaria: immune evasion by parasites. Int J Biochem Cell Biol. 37(4): p. 700-6.

[Link to Abstract](#)

Qari, S.H. et al. (1998). Predicted and observed alleles of Plasmodium falciparum merozoite surface protein-1 (MSP-1), a potential malaria vaccine antigen. Mol Biochem Parasitol. 92(2): p. 241-52.

[Link to Abstract](#)

Burns, J.M. et al. (1989). A protective monoclonal antibody recognizes a variant-specific epitope in the precursor of the major merozoite surface antigen of the rodent malarial parasite Plasmodium yoelii. J Immunol. 142(8): p. 2835-40.

[Link to Abstract](#)

Smith, J.D. et al. (1995). Switches in expression of Plasmodium falciparum var genes correlate with changes in antigenic and cytoadherent phenotypes of infected erythrocytes. Cell. 82(1): p. 101-10.

[Link to Abstract](#)

Flick, K. et al. (2004). var genes, PfEMP1 and the human host. Mol Biochem Parasitol. 134(1): p. 3-9.

[Link to Abstract](#)

Williamson, W.A. et al. (1978). Impairment of the immune response to vaccination after acute malaria. Lancet. 1(8078): p. 1328-9.

[Link to Abstract](#)

Takeda, K. et al. (2003). Toll-like receptors. Annu Rev Immunol. 21: p. 335-76.

[Link to Abstract](#)

Urban, B.C. et al. (1999). Plasmodium falciparum-infected erythrocytes modulate the maturation of dendritic cells. Nature. 400(6739): p. 73-7.

[Link to Abstract](#)

Ocana-Morgner, C. et al. (2003). Malaria blood stage suppression of liver stage immunity by dendritic cells. J Exp Med. 197(2): p. 143-51.

[Link to Abstract](#)

Omer, F.M et al. (2003). Differential induction of TGF-beta regulates proinflammatory cytokine production and determines the outcome of lethal and nonlethal Plasmodium yoelii infections. J Immunol. 171(10): p. 5430-6.

[Link to Abstract](#)

Shevach, E.M. (2002). CD4+ CD25+ suppressor T cells: more questions than answers. Nat Rev Immunol. 2(6): p. 389-400.

[Link to Abstract](#)

Hisaeda, H. et al. (2004). Escape of malaria parasites from host immunity requires CD4+ CD25+ regulatory T cells. Nat Med. 10(1): p. 29-30.

[Link to Abstract](#)

Download images for this case



Plasmodium Falciparum Malaria

1 file(s) 828.07 KB

[Download](#)

Evaluation – Questions & answers

What is the diagnosis?

Severe P.falciparum malaria, which has progressed to cerebral malaria.

With regards to parasitized erythrocytes which endothelial receptors do they bind to resulting in occlusion of microvessels?

CD36 and intercellular adhesion molecules-1 (ICAM-1).

What are the three ways that infected erythrocytes can bind to occlude microvessels?

Sequestration- binding of infected erythrocytes to receptors.

Rosetting- infected erythrocytes stick to uninfected erythrocytes

Clumping- infected erythrocytes stick together

What is the benefit of occlusion of microvessels?

It is an evasion strategy which allows the cells to escape circulating to the spleen where infected cells would be detected and destroyed.

Which organs are most affected by occlusion of microvessels?

In particular the endothelial lining of capillaries in the brain, kidneys, gut and liver are affected by occlusion of microvessels.

Describe the immune response required to neutralize malaria parasites at each stage during their development.

Sporozoites – Antibody

Maturing hepatic shizonts – CD8+ T cell

Merozoite – Antibody

Gametocyte – Antibody

Download images for this case



Plasmodium Falciparum Malaria

1 file(s) 828.07 KB

[Download](#)