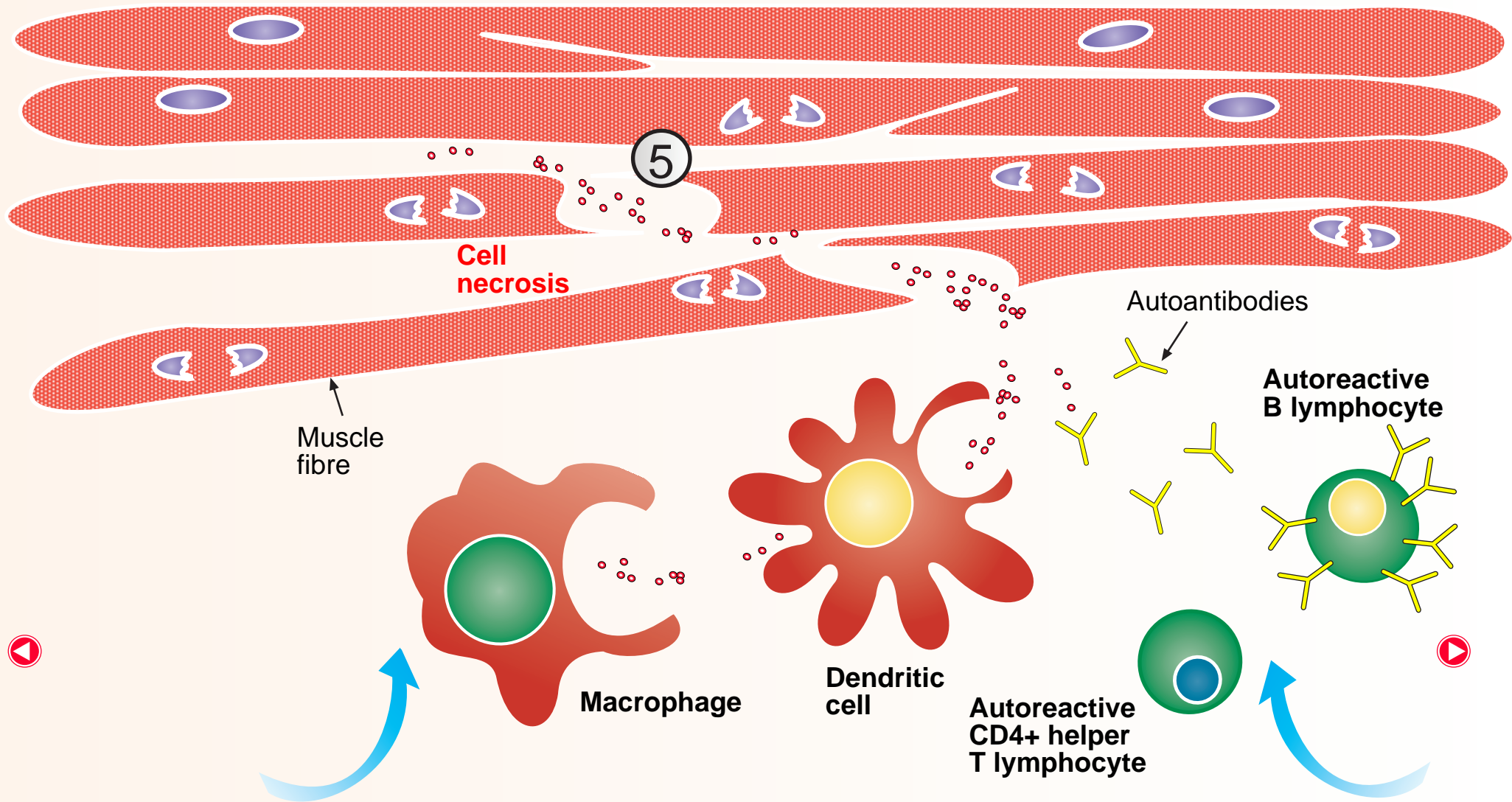


Muscle fibre necrosis and inflammation



In dermatomyositis, the destruction of the capillaries in muscle leads to necrosis of the muscle fibre cells due to lack of oxygen and nutrient supply. The necrotic muscle fibre cells attract dendritic cells and macrophages which engulf muscle derived intracellular antigens and this leads to the generation of secondary autoimmune antibody responses to muscle-specific antigens via activation of autoimmune B cells by autoimmune CD4+ helper T lymphocytes. There is an infiltration of CD4+ helper T lymphocytes and B lymphocytes into inflamed muscle that promotes phagocytosis and antibody production.

