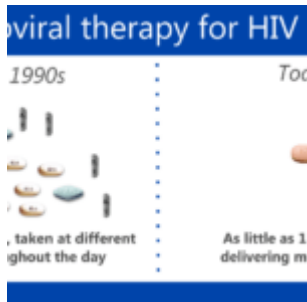


Is this treatment failure or malnutrition



- [Patient presentation](#)
- [History](#)
- [Differential Diagnosis](#)
- [Examination](#)
- [Investigations](#)
- [Discussion](#)
- [Final outcome](#)
- [Evaluation - Questions & answers](#)

Patient presentation

- HIV positive 11 years and 10 months old male, vertically infected from his mother.
- [WHO stage IV with Immunological stage 3 disease.](#)
- Patient was treated with dual therapy for 1 month and then developed severe gastroenteritis and vomiting.
- Unable to tolerate oral fluids he was admitted to hospital

Acknowledgement

This case study was kindly provided by Dr Lee Fairlie (nee Kleynhans) MBChB DCH FCpaeds(SA) Wits Paediatric HIV Clinics, Chris Hani Baragwanath Hospital

History

In March 2006 an 11 years and 9 months old patient presented to private GP after recurrent hospital admissions for pneumonia. At this time he weighed 23 kg (<3rd percentile; 57% expected weight for age) and was classified as wasted.

Tests conducted:

- CD4=40 (absolute count)
- Normal CXR
- PPD negative
- Sputum AFB's negative

TB excluded based on these results.

Patient was started on dual therapy:

- AZT 100mg po bd
- 3TC 5ml po bd

GP was already treating mom for HIV with HAART. She was also classified as WHO stage IV with Immunological stage 3 disease and TB was excluded.

Differential Diagnosis

- Viral or bacterial gastroenteritis made worse by underlying chronic HIV-related diarrhoea, possible causative organisms include *Cryptosporidium parvum*/ *Giardia lamblia*/ *Isospora belli*.
- Immune Reconstitution Inflammatory Syndrome (IRIS) – based on rapid deterioration after 1 month of starting ART.
- Opportunistic infections such as MAC (*Mycobacterium Avium Complex*).
- Poor food, drug and nutrient absorption because of HIV related diarrhoea.
- Lactic acidosis (although unlikely because he was not on

treatment long enough and AZT does not typically cause this).

- Drug toxicity.

Examination

On admission to hospital patient was

- Moribund
- Wasted
- Dehydrated 10%

There was a strong clinical suspicion of hypokalaemia based on:

- Reduced tone, reflexes difficult to elicit.
- Distended abdomen with scanty bowel sounds suggesting a hypokalaemic ileus.

The rest of the examination was non-contributory.

Investigations

- $K^+ = 1 \text{ mmol/L}$ ($3.3\text{-}5.0 \text{ mmol/L}$)
- Rest of U&E = *normal*
- Lactate = *normal*
- Mild transaminitis

Discussion

Treatment and management

In Hospital

- Patient was admitted to High Care where he was given intravenous potassium
- During his hospital stay he missed [ARV's](#) for 1 day

- After patient's potassium recovered he was transferred to Hospice for respite care and psychosocial intervention

At Hospice

- In hospice he received nasogastric tube (NGT) feeds in the form of Peptamen, a peptide-based elemental diet for the nutritional support of GI-impaired children. This is absorbed much more easily than food and helps the gut recover, thereby increasing food and drug absorption.
- Two months on dual therapy his CD4 count increased to 117 and viral load was undetectable.

Treatment Evaluation

The ARVs he was on were noted to be an inadequate dose for the patient:

- AZT – 100mg po bd (inadequate dose, should be 200mg bd for patient's weight)
- 3TC – 5ml po bd (should have been on 8 ml bd)
- No 3rd drug had been added

Treatment and follow up

At this stage the question was what to do with his ARV's? Although the therapy he was on was working as evidenced by his climbing CD4 count, suppressed viral load and general health improvement the likelihood of resistance occurring if this is used as long term treatment is high.

The decision was made to start him on triple therapy using corrected dosages appropriate for his body weight. He continued with AZT and 3TC and efavirenz was added to the regimen because his CD4 was improving and he was virally suppressed.

After two weeks he was transferred from Hospice to a hospital close to where his mother works. He has continued with this regimen and he has been followed up regularly.

Outcome

- His progress has remained very good, his mother is still motivated and compliant and he has continued his triple therapy without interruptions.
- His weight has steadily increased to 34.5 kg (just below 3rd percentile)
- He has been clinically well and has required no intermittent admissions.
- His CD4 count has continued to increase with the last CD4 count at 160 (10.2%)
- Viral load has remained undetectable at < 25 copies

Final outcome

One year later the patient continues to do excellently on triple therapy, he is gaining weight, he has maintained viral load suppression and his CD4 count continues to increase. He is followed up regularly at the same hospital and his mother has remained compliant with his therapy and appears to be compliant with her own therapy too.

Evaluation – Questions & answers

What is the most likely diagnosis for this case?

Poor food, drug and nutrient absorption because of HIV related diarrhoea.

How does absorption of nutrients and drugs occur in a normal functioning Gastrointestinal Tract (GIT)?

Most of the breakdown and absorption of nutrients takes place in the small intestine. Numerous finger-like villi project into the lumen of the gut and are mostly made up of specialised absorptive epithelial cells (enterocytes) and goblet cells that produce mucous to protect and lubricate the epithelial cell layer and absorb nutrients and drugs.

How does HIV affect the absorption of nutrients and drugs from

the GIT?

HIV infection in the gut causes malabsorption of nutrients due to the disruption in the normal development of intestinal villi. This comes about with activation of the mucosal immune system due to HIV replication of the CD4+ T helper lymphocytes in the lamina propria and the subsequent production of pro-inflammatory cytokines. This process results in a disruption of gut epithelial cell development, most notably leading to villous atrophy and an increase in gut permeability to microbes and microbial antigens. The consequences are thus malabsorption of nutrients and drugs due to the reduced absorptive surface area.

How does the immune system function in a normal functioning GIT?

In a normal functioning GIT we have a number of specialised cells involved in antimicrobial defense and immunity. There are the crypts of Lieberkuhn which contain epithelial stem cells that generate a variety of cell types. These stem cells are protected by Paneth cells that secrete antimicrobial defense molecules. The small intestine also carries out luminal antigen sampling in secondary lymphoid tissue known as Peyer's Patches. The surface of Peyer's patches are composed of specialised epithelial cells known as M cells (microfold cells) capable of delivering intact antigens by transcytosis to antigen presenting cells such as dendritic cells and macrophages. Antigen presentation and activation of T and B cells occurs in the lymphoid follicle in close proximity to the epithelial cell layer.

How does HIV affect the immune system in the GIT?

The release of pro-inflammatory cytokines due to the activation of the mucosal immune system by HIV increases the gut permeability to microbial organisms and antigens and further stimulates the immune system enhancing HIV replication. Furthermore antigen-presentation in Peyer's Patches is greatly reduced in HIV infection. This is due to a failure in maintaining the homeostasis of immune cells in the lymphoid follicles and the structure and function of the tissue. Depletion of CD4+ T helper cells in the lamina propria reduces the recruitment of new T and B lymphocytes into the

lymphoid tissue. In the absence of immune cell proliferation in the lymphoid follicle the physical size of the Peyer's Patches are reduced.

What are the benefits of triple therapy over dual therapy?

Repeated trials have shown that the combination of a protease inhibitor plus two nucleoside analogue reverse transcriptase inhibitors or HAART is significantly more effective in reducing the occurrence of AIDS-defining illnesses or death in patients with advanced HIV disease than dual therapy. HAART reduces disease progression, reduces opportunistic infections and cancers and decreases death by more than 50 %. Furthermore the benefit of HAART increases over time.